



Hiperikum Perforatum Ekstresinin Topikal Yanık Hasarı Üzerine Olan Etkileri; İyodin ile Karşılaştırmalı Çalışma

The Effects of Hypericum Perforatum Extract on Topical Burn Injury: A Comparative Study with Iodine

Hiperikum Perforatumun Yanıktaki Rolü / The Role of Hypericum Perforatum on Burns

Alper Çelik¹, Ömer Faik Ersoy¹, H. Ayhan Kayaoğlu¹, Namık Özkan¹, Neşe Lortlar², Suna Ömeroğlu², Ebru Arabacı Çakır³

¹Department of General Surgery, Gaziosmanpaşa University Faculty of Medicine, Tokat, ²Department of Histology and Embryology, Gazi University Faculty of Medicine, Tokat, ³Department of Pathology Ankara Atatürk Training and Research Hospital, Ankara, Turkey.

Özet

Amaç

Çalışmamızda sıçanlarda oluşturulan termal yanık modelinde topikal Hiperikum perforatum (HP) ekstresinin etkilerini incelemeyi ve topikal iyodin tedavisi ile karşılaştırmayı amaçladık.

Gereç ve Yöntemler

Wistar-Albino sıçanların sırt derisinde iki adet üçüncü derece yanık alanı oluşturuldu. Kontrol grubuna tedavi verilmezken tedavi gruplarına iyodin veya HP ekstresi verildi. Yedi gün sonra yanık alanları makroskopik olarak değerlendirilerek ülserasyonlar ölçüldü. Tüm hayvanlarda yara iyileşmesinin histolojik göstergeleri ve Transforming Growth Factor- β (TGF- β) seviyeleri ölçüldü.

Bulgular

Tedavi gruplarında ülserasyon alanları anlamlı derecede daha küçüktü. İyodin grubunda %23.94 ($p=0.008$) ve HP grubunda %42.89 azalma saptandı ($p<0.0001$). TGF- β seviyeleri HP grubunda hafif bir azalma gösterdi. Kollojenizasyon ve re-epitelizasyon HP grubunda anlamlı oranda fazla olmak üzere her iki tedavi grubunda da artmıştı. HP grubunda fibroblast proliferasyonu da daha yüksek seviyedeydi. İyodin tedavisinin daha yüksek oranda nekroza neden olduğu gözlemlendi.

Sonuç

HP ekstresinin topikal yanık hasarı üzerine faydalı olabileceği sonucuna varılmıştır.

Anahtar Kelimeler

Topikal Yanık, İyodin, Hiperikum Perforatum Ekstresi, Yara İyileşmesi, TGF- β .

Abstract

Aim

We aimed to assess the efficacy of topical Hypericum perforatum (HP) extract and compare with topical iodine in a rat model of thermal skin injury.

Material and Methods

Wistar-Albino rats were subjected to two separate heat-induced third degree burn injuries on dorsal skin. Control group was left untreated, and treatment groups received either topical iodine or HP. Seven days later injured areas were macroscopically examined, and ulcerations were calculated. Histological indices of wound healing and expression of Transforming Growth Factor- β (TGF- β) were analyzed in each animal.

Results

Treatment groups had significantly smaller areas of ulceration. We observed 23.94% reduction in iodine ($p=0.008$) and 42.89% reduction in HP treated rats ($p<0.0001$). Transforming Growth Factor- β levels were slightly reduced in HP group. Collagenisation and re-epithelization were improved in both treatment groups with significant superiority in HP group. Fibroblast proliferation was better in the same group. It was observed that iodine treatment led to higher rates of necrosis.

Conclusions

We state that HP extract might be beneficial for the treatment of topical burn injury.

Keywords

Topical Burn, Iodine, Hypericum Perforatum Extract, Wound Healing, TGF- β .

DOI: 10.4328/JCAM.249 Received: 10.04.2010 Accepted: 05.05.2010 Printed: 01.09.2010 J.Clin.Anal.Med.2010;1(3):4-7

Corresponding Author: Alper Çelik, Gaziosmanpaşa University Faculty of Medicine Department of General Surgery, 60100 Tokat, Turkey.

Phone: +905327059540 Fax: +903562133179 E-mail: doktoralper@hotmail.com

Introduction

Thermal burns and related injuries are one of the most common causes of disability and death in civil environments and constitute the majority of burns admitted to hospital. Within these admissions pediatric and geriatric subjects are more commonly encountered than others [1]. Thermal burns are usually caused by heat, rarely by cold and chemicals. The severity of injury is highly dependent on temperature, duration, skin thickness, area exposed, and presence of clothing [2]. Patients with severe burn injuries may require prolonged reconstructions, rehabilitation, and psychological support [3]. Goal of treatment in burn injury is not only improved survival, but also local wound healing, cosmesis and providence of a well rehabilitated and normally functioning injured area. Civil burns with less than 15% of total body surface area constitute the majority of burn cases and are usually treated by topical wound dressings or ointments [4,5]. Beside cosmesis and wound healing, control of infections is also a major determinant of healing in burn injury. From this aspect, yet there is no single drug that can fulfill the criteria described above. Silver sulphodiasine, iodine and antibiotic containing creams are some of the commercially available formulations used in burn patients. Iodine, because of its marked antibacterial properties, is used in the treatment of thermal burns, alkylating agent and mustard-gas induced injuries [6]. In the present study we compared the effects of Hypericum perforatum (HP)-a medicinal plant-with iodine. HP contains flavonoids, phenolic acids, etheric lipids, carotene and vitamin E. One of its phenolic constituents (Hyperforin) displays antibacterial, anti-oxidative and antiinflammatory effects, and also prevents lipo-oxygenation [7-10]. Recent evidence also suggests analgesic and antidepressive effects of Hypericum derivatives [11,12]. In the present study we evaluated the effects of treatment agents by macroscopic ulceration, TGF- β expressions, and histological indices as indicators of heat-induced skin injury and wound healing. These parameters have been studied extensively in previous reports regarding burn injury. To our knowledge our study is the first to demonstrate the effects of HP in burn injury.

Material and Methods

Protocol of this study was approved by the institutional ethical committee. All procedures and follow-up were held according to local animal studies research center regulations. Thirty Wistar-albino rats of both sex weighing 240-360 g were randomly allocated to three groups (n=10 per group). Two to three rats of same sexes were housed in separate wire cages with free access to food and water under standard laboratory conditions (room temperature 23°C, 12 h light-dark cycles). Rats were fasted 12 h before surgery, but had free access to water.

Experimental Procedure and Evaluation

Rats received a third degree scald burn, as previously described [13]. Briefly, rats were anesthetized by 75 mg/kg ketamin hydrochloride and 10 mg/kg xylazin, and dorsal hair was shaved. Burn injury was performed at two separate sites exposing to heat source (boiling water at 75 °C, for 7 seconds) by the well system. Wells were cylindrical plastic tubes with 0.5 cm diameter. One ml of boiling water was introduced into the tubes and kept on the previously marked area for 10 seconds, and aspirated. All animals were resuscitated with Ringer's lactate solution (2 mL / 100 g, IP (Intraperitoneal) and naproxen sodium was used for analgesia. After the heat application both exposed areas were immediately treated with iodine or HP extract. Sham treated rats were

resuscitated with Ringer's lactate only. All treatment agents were kept in room conditions to minimize the cooling effect. Daily wound examination and treatment was accomplished in treatment arms in an induction chamber under inhalation anesthesia using sevofluorane (3 ml/min) at 9 a.m. every day. Both agents were gently applied using a sterile tongue blade as a transparent cover over the heat exposed areas. The amounts of the applicatives were 5 ml for all groups, per animal. Treatment groups were treated with iodine or HP extract. After application the rats were kept in the chamber approximately 10 minutes and observed until their dressings dried. At post-operative 7th day rats were re-anesthetized by ketamin and xylazin, and dermal specimens were resected with wide margins. All specimens were gently manipulated by hand. Ulceration area was drawn on acetate papers and measured as mm². Thereafter, rats were sacrificed by decapitation. Both areas were kept in formalin. One was sent for histological analysis and the other for evaluation of TGF- β levels.

Medical Agents

Extract of fresh, organically grown Hypericum perforatum tincture (St. John's Wort) was obtained from Bioforce Ltd. (A. Vogel Comp. Irvine, Scotland). The hypericin content is 4-12 mg per 100g and minimum flavonoid content is 200 mg per 100g. Povidone iodine 10% (Isosol, Merkez Lab, Istanbul) was used in iodine group.

Histological Analysis: One skin section from each rat was evaluated according to a previously modified system [13]. Skin specimens fixed in 10% formaldehyde were embedded in paraffin, sectioned at 5 μ m, stained with hematoxylin-eosin and evaluated under light microscope. For each specimen, epidermal parameters (subepidermal microblister formation, necrosis, crust formation, hyperkeratosis, acanthosis) and dermal parameters (hemorrhage, inflammation, necrosis, fibrosis) were assessed semi-quantitatively by assigning a score of 0 to 4 representing unremarkable, minimal, mild, moderate and marked changes. In addition, the areas of epidermal acanthosis were estimated using grades of 0-6 as follows: 0-no acanthosis; 1-less

Table 1. List of epidermal and dermal parameters used for quantitative histopathological evaluation.

Grading for Epidermal Parameters	Grading for Dermal Parameters
1-Subepidermal microblister formation. (0-4)	1-Hemorrhage (0-4)
2-Necrosis (0-4)	2-Inflammation (acute and subacute) (0-4)
3-Crust formation (0-4)	3-Necrosis (0-4)
4-Hyperkeratosis (0-4)	4-Fibrosis (0-4)
5-Acanthosis (epidermal hyperplasia) (0-6)	

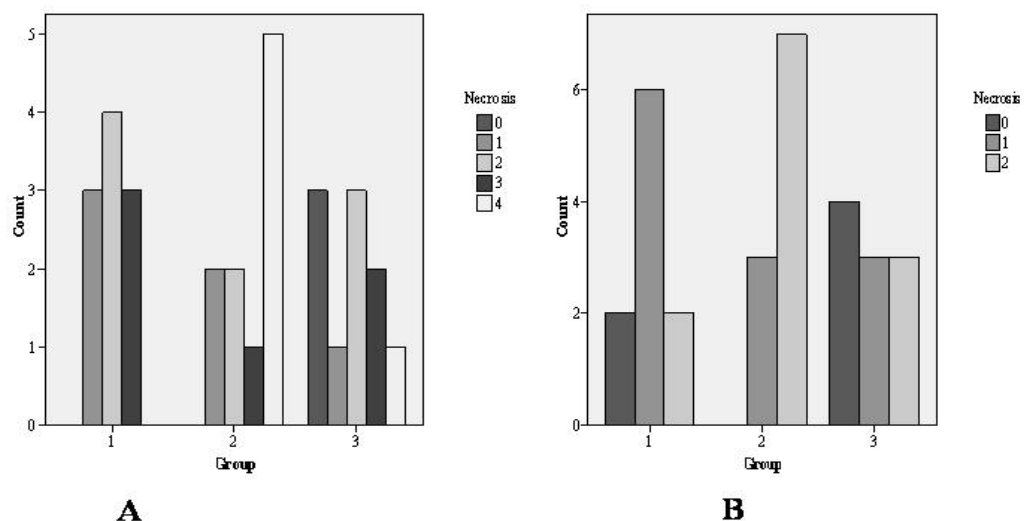


Figure 1. Scores of epidermal (A) and dermal necroses (B) were the highest in iodine treated group. HP significantly improved both epidermal and dermal necrosis compared to others (Group 1: Control, 2: Iodine, 3: HP).

than 1/3 of the epidermal area acanthotic, the remainder necrotic or ulcerated; 2- approximately 1/3 acanthotic, the remainder necrotic or ulcerated; 3- approximately 1/2 acanthotic, the remainder necrotic or ulcerated; 4- more than 1/2 but less than 2/3 acanthotic, the remainder necrotic or ulcerated; 5- more than 2/3 acanthotic, the remainder necrotic; 6-diffuse acanthosis. Epidermal healing parameters were acanthosis and hyperkeratosis. Parameters indicating epidermal injury were microblister formation, crust, and necrosis. Dermal healing parameter was fibroblastic proliferation. Factors indicating dermal injury were hemorrhage, inflammation and necrosis. These histological parameters and their grading scales are listed in Table 1. Re-epithelization and collagenisation were evaluated using High Score System by two independent histologists in double-blind manner. Both indices were scored as 1; none, 2; mild, 3; moderate, 4; severe. Mean score for each specimen was multiplied by five (the number of area inspected), and final data was used for statistical analysis.

TGF- β Assessment (Immunohistochemistry)

Sections, 5 μ thick were incubated for one night at 37° C and for 1 h at 60 °C. Xylol application (15 min) was performed twice. The slides were then placed in 96% absolute alcohol and 80 % ethanol for 10 min, followed by distilled water, twice for 5 min, and boiled in high temperature microwave oven in 10% citrate buffer. After 20 min at room temperature, tissues were enrolled with a pap-pen (hydrophobic pen), washed with distilled water and phosphate-buffered saline (PBS), and hydrogen peroxide was added dropwise. This step was followed by ultra V block and application of primary antibody (TGF- β 3 /Labvision / NeoMarkers Corporation, Fremont CA, USA) for 1 hour. Samples were washed with PBS, a post-PBS level was applied and specimens were placed in AEC chromogene for 10 minutes. Finally counterstain with Mayer's haematoxylin was performed for 5 min. All slides were evaluated with Leica DM 400 B light microscope (Wetlar, Germany). For the lymphocyte / inflammatory cell ratio, five microscopic fields were selected randomly in each slide at x400 magnification. Cells were then counted with specialized microscopy program (Leica Q win analysis program) and used for statistical analysis.

Statistical Analysis

Homogeneity of variances was assessed using Levene test. Statistical significance was assessed by one-way ANOVA following Tukey HSD and pathological parameters were assessed by chi-square test (likelihood ratio). A difference in p value less than 0.05 was considered significant.

Results

Macroscopic Evaluation

All rats were sacrificed on postoperative seventh day and heat induced areas were macroscopically evaluated for the presence and severity of burn injury and ulceration area. Mean ulceration area was 53.05 ± 6.59 mm² in control, 40.35 ± 7.76 mm² in iodine, and 30.3 ± 6.16 mm² in HP groups ($F = 27.535$, $p < 0.0001$). Iodine treatment compared to control ($p=0.001$), and HP treatment compared to both groups showed better results ($p < 0.0001$ for control, $p=0.008$ for iodine).

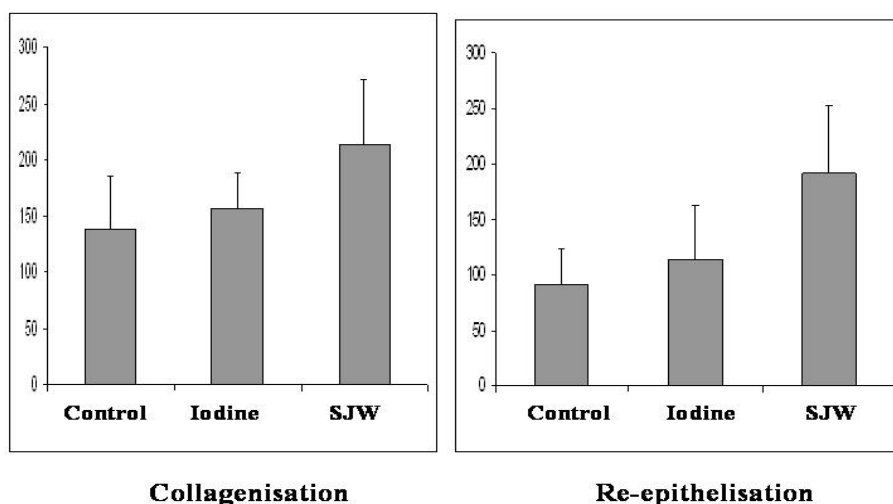


Figure 2(A-B). Re-epithelization and collagenisation scores. Both scores were significantly improved in HP treated group ($p = 0.005$ and $p=0.007$, respectively). Abbreviations; Re-ep: Re-epithelization, SJW: St. John's Wort: Hypericum perforatum extract.

dine treatment compared to control ($p=0.001$), and HP treatment compared to both groups showed better results ($p < 0.0001$ for control, $p=0.008$ for iodine).

TGF- β Analysis

Mean TGF- β immunoreactivity was 43.05 ± 17.42 in the control, 44.16 ± 24.96 in iodine, and 40.25 ± 12.4 in HP groups. SJW treated rats expressed lower levels of TGF- β activity. But the difference was not significant ($F=0.536$, $p=0.591$).

Histological Evaluation

We analyzed epidermal and dermal indices of injury / healing separately. Among epidermal injury parameters microblister formation was similar in all groups ($p=0.505$). Epidermal crust formation was markedly higher in untreated rats. Severe (grade 4) crust formation was detected in 50% of control group. Treatment arms were free of severe (grade 4) crust formation. Increased crust formation (grade 3) was similar in both treatment groups (20% vs. 30%) and both treatment options significantly improved rates of

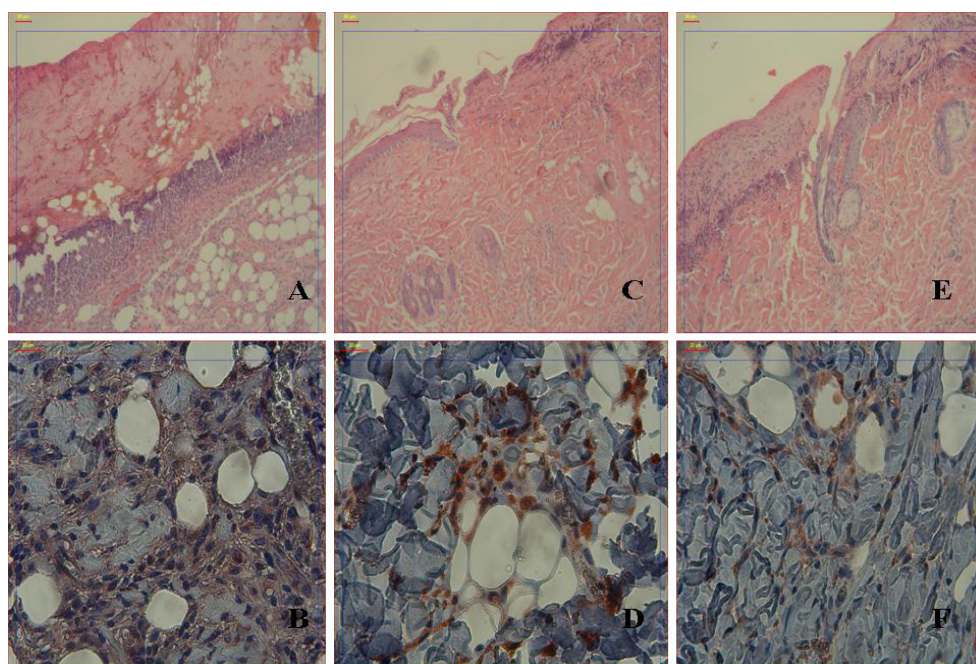


Figure 3(A-F). Representative sections from control group indicating marked edema and inflammatory cell infiltration (A), and moderate TGF- β immunoreactivity (B), from iodine group showing weak re-epithelization, dense inflammatory cell infiltration, disorganized collagen fibers (C), and moderate TGF- β expression (D), and from HP treated animals depicting improved re-epithelization, mild inflammatory cell infiltration (E), and well organized collagen fibers with mild TGF- β positivity (F). Figures 4A-C-E: Hematoxylin-Eosin, x100, Figures 4B-D-F: TGF- β expression x400.

crust formation ($p=0.004$). Epidermal and dermal necroses were the highest in iodine treated group. We observed highest scores of epidermal necrosis (grade 4) in 50%, and dermal necrosis in 70% of iodine arm, with significant difference ($p=0.029$). HP application improved both epidermal and dermal necrosis compared to other groups ($p=0.036$), and resulted in 30% epidermal and 40% dermal necrosis-free wound healing (Figure, 1 A-B).

Levels of epidermal healing parameters including hyperkeratosis and acanthosis were similar between groups ($p=0.054$, 0.055 , respectively). However, poor acanthosis (grade 1) was more common (40%) in the control group. Dermal injury indices including acanthosis, hemorrhage and inflammation were similar in all rats ($p=0.301$, 0.22 , 0.99 , respectively). Fibroblast proliferation, the dermal healing index was similar between all groups ($p=0.151$). But, improved fibroblast proliferation (grade 2) was seen only in HP treated rats. Both collagenisation and re-epithelization scores were significantly better in HP treated rats ($p=0.005$ and $p=0.007$, respectively). Re-epithelization scores were 137 ± 47.85 , 156 ± 32.04 , 213 ± 58.69 ; and collagenisation scores were 91 ± 32.12 , 113 ± 49.67 , 191 ± 60.63 for control, iodine and HP groups, respectively (Figure 2, A-B). Demonstrative sections of inflammation, re-epithelization, collagenisation and TGF- β expressions are shown in Figure 3, A-F.

Discussion

Major thermal injury is associated with significant physiologic stress on the organism, producing a hypermetabolic state leading to alterations in carbohydrate and nitrogen metabolism [14-16]. This state is further complicated by microorganisms in the burned area. In the present study we did not observe any septic condition like purulent discharge. Gross pathological examination showed a significant decrease of ulceration in both treatment groups, and HP application was more potent than iodine.

Wormser, et al investigated the efficacy of iodine formulations on heat induced skin injury, and stated that iodine treatment leads to 65-80% reduction in burn injury related skin ulcerations [17]. We also observed a reduction of gross skin ulcers in iodine treated rats, and this improvement was confirmed with better crust formation, epidermal acanthosis, collagenisation, and re-epithelization compared to control animals. But, the percentage of skin survival was much less than that reported by Wormser, et al, and furthermore histological indices of necrosis were markedly worse in the iodine treated group. It is inevitable to accept the beneficial impacts of iodine on wound healing in thermal injury. But, HP application resulted in less ulceration, necrosis, and far most improved collagen formation and re-epithelization compared to iodine.

In addition to macroscopic ulceration we evaluated local TGF- β expression in all rats in order to further evaluate the effects of these on burn injury. This is the first study to assess the effect of HP on TGF- β levels in burn injuries. TGF- β is a cytokine from TGF superfamily that plays important roles in immune function, and wound healing by regulating epithelial cell growth, motility, differentiation, and apoptosis [18,19]. Besides the aforementioned

activities it regulates angiogenesis, haematopoiesis, cell cycle progression and cellular migration [20-22]. For these reasons it has essential functions in regeneration, inflammation and wound healing. The ischemic effects and cell death after thermal injury have been reported to prolong until the end of the first week. The local inflammatory and systemic responses can also be identified during the same period [23]. TGF- β levels increase on day 3 and continues to increase until the end of one week after burn [24,25]. TGF- β levels are related to depth of burn and high levels of TGF- β are indicative of severe burn, prolonged wound healing and hypertrophic scar formation [26,27]. Sakallıoglu, et al have shown that full thickness burns express higher levels of TGF- β , indicative of burn induced immunosuppression and peak around post-burn day seven [26]. In the current study, although insignificant, HP treatment reduced TGF- β levels compared to iodine treatment. This result suggests a supportive effect of HP in wound healing. Furthermore, improved skin survival in HP- treated rats correlated well with better re-epithelization and collagenisation. In the control group, there were marked dermal edema with disorganized collagen fibers and no epithelization. Marked edema and unimproved epithelization was also constant among iodine treated animals. These rats had mild collagenisation. On the other hand, HP- treated rats showed improved fibrosis, moderate epithelization, and well organized collagen fibers. Furthermore, although it is not significant, HP- treated animals demonstrated lower levels of TGF- β , as compared to others. Another possible explanation for the better results seen in HP- treated rats might be its role on wound hydration, which provides a moist environment for the injured site. Previous reports have documented the importance of hydration on wound healing [28]. In our experimental protocol we examined all rats for an additional 10 minutes in the induction chamber and observed that the wound site in iodine treated rats was almost entirely dry by the end of this period. Hydration assists in retaining of moisture and thereby, supports re-epithelization, reduces necrosis, and provides a barrier against bacteria [29,30]. Wound healing accelerates in a moist environment [31]. We eventually observed that HP extract providing a moist, gelatinous environment that well correlated with the healing quality, as confirmed by increased collagenisation, epithelization, and decreased ulceration, necrosis, and TGF- β levels.

Our data suggests that, utilization of supportive strategies like HP extract may provide promising outcomes on burn injuries, and modification of topical agents for optimizing wound healing might enhance our approach to this particular field. Possible mechanisms are improved collagenisation, re-epithelization, and provision of a moist, well hydrated environment. We believe that our findings can be important for developing new treatment strategies and clinical studies in thermal injuries.

Acknowledgements

The authors would like to thank to Miss Marie Cosgrove from Surugadai University, Japan for English revision of the manuscript.

References

- Muller MJ, Herndon DN. The challenge of burns. *Lancet* 1994; 343: 216-220.
- Moritz A, Henriques F. Studies of thermal injury II. The relative importance of time and surface temperature in the causation of thermal burns. *Am J Pathol* 1947; 23: 695.
- Rose JK, Herndon DN. Advances in the treatment of burn patients. *Burns* 1997; 23: 19-26.
- Guegniaud PY, Carsin H, Bertin-Maghit M, et al. Current advances in the initial management of major thermal burns. *Intensive Care Med* 2000; 26: 848-56.
- Acikel C, Oncul O, Ulkur E, et al. Comparison of silver sulfadiazine 1%, mupirocin 2%, and fusidic acid 2% for topical antibacterial effect in methicillin-resistant staphylococci-infected, full-skin thickness rat burn wounds. *J Burn Care Rehabil* 2003; 24:37-41.
- Wormser U. Early topical treatment with povidone-iodine ointment reduces and sometimes prevents skin damage following heat stimulus. *Burns* 1998; 24: 383.
- Beerhuus L. Hyperforin. *Phytochemistry* 2006; 67: 2201-7.
- Schemper CM, Windeck T, Hezel S, et al. Topical treatment of atopic dermatitis with St. John's wort cream - a randomized, placebo controlled, double blind half-side comparison. *Phytotherapy* 2003; 10: 31-7.
- Feisst C, Albert D, Verotta L, et al. Evaluation of hyperforin analogues for inhibition of 5-lipoxygenase. *Med Chem* 2005;1: 287-91.
- Genovese T, Mazzon E, Di Paola R, et al. Hypericum perforatum attenuates the development of cerulein-induced acute pancreatitis in mice. *Shock* 2006; 25: 161-7.
- Randlov C, Mehlsen J, Thomsen CF, et al. The efficacy of St. John's Wort in patients with minor depressive symptoms or dysthymia - a double-blind placebo-controlled study. *Phytotherapy* 2006; 13: 215-21.
- Uebelhack R, Blohmer JU, Graubaum HJ, et al. Black cohosh and St. John's Wort for climacteric complaints: A randomized trial. *Obstet Gynecol* 2006; 107:247-55.
- Wormser U, Sintov A, Brodsky B, et al. Protective effect of topical iodine preparations upon heat-induced and hydrofluoric acid-induced skin lesions. *Toxicol Pathol* 2002; 30: 552-8.
- Wolfe RR, Durkot MJ, Allsop JR, et al. Glucose metabolism in severely burned patients. *Metabolism* 1979; 28: 1031-8.
- Burke JF, Wolfe RR, Mullany CJ, et al. Glucose requirements following burn injury. *Ann Surg* 1979; 190: 274-85.
- Bell SJ, Molnar JA, Krasker WS, et al. Prediction of total urinary nitrogen from urea nitrogen for burned patients. *J Am Diet Assoc* 1985; 85: 1100-4.
- Wormser U, Brodsky B, Green BS, et al. Protective effect of povidone-iodine ointment against skin lesions induced by sulphur and nitrogen mustards and by non-mustard vesicants. *Arch Toxicol* 1997; 71: 165-170.
- Massague J, Cheifetz S, Laiho M, et al. Transforming growth factor-beta. *Cancer Surv* 1992; 12: 81-103.
- Coffey Jr RJ, Derynck R, Wilcox JN, et al. Production and auto-induction of transforming growth factor-alpha in human keratinocytes. *Nature* 1987; 328: 817-20.
- Bikfalvi A. Significance of angiogenesis in tumour progression and metastasis. *Eur J Cancer* 1995; 31: 1101-4.
- Sporn MB, Roberts AB. Transforming growth factor-beta: recent progress and new challenges. *J Cell Biol* 1992;119: 1017-21.
- Kulkarni AB, Huh CG, Becker D, et al. Transforming growth factor beta 1 null mutation in mice causes excessive inflammatory response and early death. *Proc Natl Acad Sci USA* 1993; 90: 770-4.
- Knäbl JS, Bauer W, Andel H, et al. Progression of burn wound depth by systemical application of a vasoconstrictor: an experimental study with a new rabbit model. *Burns* 1999; 25:715-21.
- Schwacha MG, Somers SD. Thermal injury-induced immunosuppression in mice: the role of macrophage-derived reactive nitrogen intermediates. *J Leukoc Biol* 1998;63:51-8.
- Varedi M, Jeschke MC, Engleider EW, et al. Serum TGF-beta in thermally injured rats. *Shock* 2001;16:380-2.
- Sakallıoglu AE, Basaran O, Ozdemir BH, et al. Local and systemic interactions related to serum transforming growth factor-b levels in burn wounds of various depths. *Burns* 2006; 32: 980-5.
- Colwell AS, Phan TT, Kong W, et al. Hypertrophic scar fibroblasts have increased connective tissue growth factor expression after transforming growth factor-beta stimulation. *Plast Reconstr Surg* 2005; 116: 1387-92.
- Atiyeh BS, Ioannovich J, Maglaci G, et al. A new approach to local burn wound care: moist exposed therapy. A multiphase, multicenter study. *J Burns Surg Wound Care* 2003;2:18-26.
- Diegelmann RF, Evans MC. Wound healing: an overview of acute, fibrotic and delayed healing. *Front Biosci* 2004;9:283-9.
- Atiyeh BS, Ioannovich J, Maglaci G, et al. The efficacy of moisture retentive ointment in the management of cutaneous wounds and ulcers: a multicellular clinical trial. *Indian J Plast Surg* 2003; 36: 89-98.
- Chen J, Han CM, Su GL, et al. Randomized controlled trial of the absorbency of four dressings and their effects on the evaporation of burn wounds. *Chin Med J* 2007; 120: 1788-91.